

## *Some anatomical studies on the nerve supply of the tail of the buffalo "Bos Bubalis L."*

**Z. A. Adam, M. R. A. Gad, M. G. Tawfik\***

*Department of Anatomy and Embryology, Faculty of Veterinary Medicine, Beni-Suef University, Beni-Suef62511, Egypt.*

**Ten tails of buffaloes were used in this study from apparently healthy adult animals. They were dissected to reveal their nerve supply. Eight photographs illustrated the results in the study. The study revealed that there are five pairs of caudal nerves, sympathetic and parasympathetic innervations of the tail are demonstrated.**

---

The importance of the buffalo among the livestock in our country as a reproductive animal initiated an increasing interest to establish more accurate and specific studies about its tail. The tail is clinically important due to the epidural analgesia could be applied within the first or the second intercoccygeal space. In spite of the anatomical studies on this region in different domestic animals conducted by many authors, there is a lack of available literatures on the vasculature of the tail region in buffaloes (El-Ayat, Hagra, Swielim and Abu Zaid, 1983 and Tawfik, 2007) and in buffalo calves (Gadre, 2000). The present study was an attempt to give a detailed description of the nerve supply of the tail in the buffaloes to facilitate the surgical interference in this region.

### **Material and Methods**

The material used in the present study included 10 tails were carefully dissected to reveal the nerves that supply the tail.

The somatic innervation of the tail was represented by five pairs of caudal nerves, however the sympathetic innervation was represented by the sympathetic trunk, caudal and impar ganglia. Meanwhile, the communicating branches from the ventral branches of the third, fourth and fifth sacral spinal nerves were contributed to the sympathetic trunk and presented the parasympathetic innervation of the tail.

### **Results**

**Nn. Caudales.** The caudal nerves left the vertebral canal through the intervertebral foramen behind the corresponding vertebra (Fig., 1-5). After emerging through the intervertebral foramen, each caudal nerve was divided into dorsal and ventral branches (Fig., 2 - 4, 8).

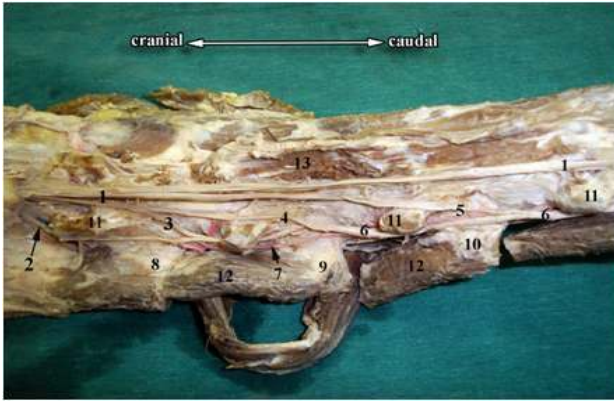
**Rami dorsales.** The dorsal branch of the first caudal nerve anastomosed with the dorsal one of the last sacral spinal nerve (Fig., 2 - 4, 8) and continued caudally to unite with the dorsal branches of the corresponding nerves of the same side, constituting the dorsal caudal nerve plexus (Fig., 1 - 4, 6, 8). The dorsal branch of the last sacral spinal nerve issued a muscular branch to innervate the adjoining dorsal muscles of the tail (Fig., 1 - 4).

**Rami ventrales.** The ventral branch of each caudal nerve passed caudoventrally, deep to the M. intertransversarii caudae, just caudal to the transverse processes of the corresponding vertebra and continued caudally on the dorsal aspect of M. sacrocaudalis ventralis lateralis and lateral to the hemal processes of the caudal vertebrae (Fig., 2 - 6). The ventral branches of the caudal nerves anastomosed together forming the ventral caudal nerve plexus (Fig., 2 - 6). Moreover, the ventral branch of the first caudal nerve joined the ventral one of the last sacral spinal nerve just after emergence of the later from the last pelvic sacral foramen (Fig., 2 - 6).

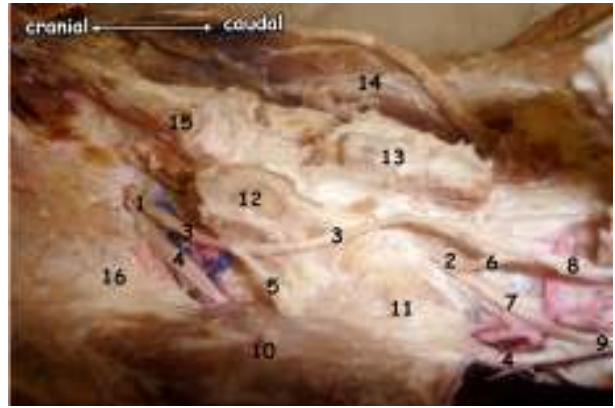
**Plexus caudalis dorsalis.** The dorsal caudal plexus (Fig., 1 - 4, 6) passed caudally between the cranial articular and transverse processes of the caudal vertebrae in accompany with the dorsolateral caudal artery (Fig., 1 - 3), where it was covered by M. sacrocaudalis dorsalis

---

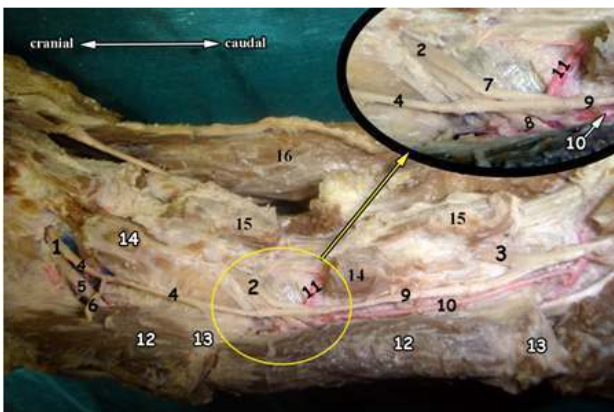
\* Corresponding author. Tel.: +20 0822322066;  
fax: +20 0822327982.  
E-mail address: [tawfik@bsu.edu.eg](mailto:tawfik@bsu.edu.eg)  
(M. G. Tawfik).



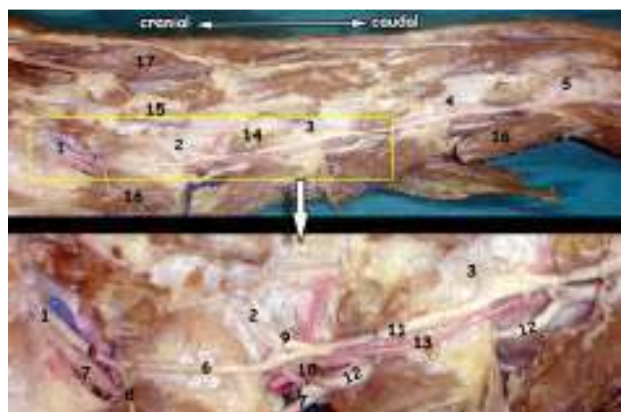
**Fig. (1):** A photograph of the sacrocaudal region of the buffalo (Dorsolateral view), after removal of the vertebral arches of the first four caudal vertebrae: 1- Nn. Caudales, 2- N. sacralis V, 3- N. caudalis I, 4- N. caudalis II, 5- N. caudalis III 6- Plexus caudalis dorsalis, 7- A. caudalis dorsolateralis, 8- Processus transversus of the first caudal vertebra, 9- Processus transversus of the second caudal vertebra, 10- Processus transversus of the third caudal vertebra, 11- Processus articularis cranialis, 12- Mm. Inter-transversarii caudae, 13- M. sacrocaudalis dorsalis medialis.



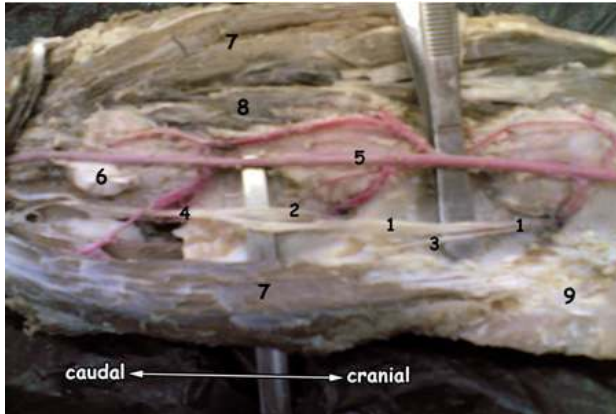
**Fig. (2):** A photograph of the tail of the buffalo (dorsolateral view), after removal of the dorsal muscles of the tail, showing origin and distribution of the first caudal and last sacral spinal nerves: 1- N. sacralis V, 2- N. caudalis I, 3- R. dorsalis N. sacralis V, 4- R. ventralis N. Sacralis V, 5- R. muscularis N. Sacralis V, 6- R. dorsalis N. Caudalis I, 7- R. ventralis N. Caudalis I, 8- Plexus caudalis dorsalis, 9- Plexus caudalis ventralis, 10- Mm. Intertransversarii caudae 11- Processus transversus of the caudal vertebra I, 12- Processus articularis cranialis 13- Processus spinosus, 14- M. sacrocaudalis dorsalis lateralis, 15- M. sacrocaudalis dorsalis medialis, 16- Processus transversus of the sacral vertebra V.



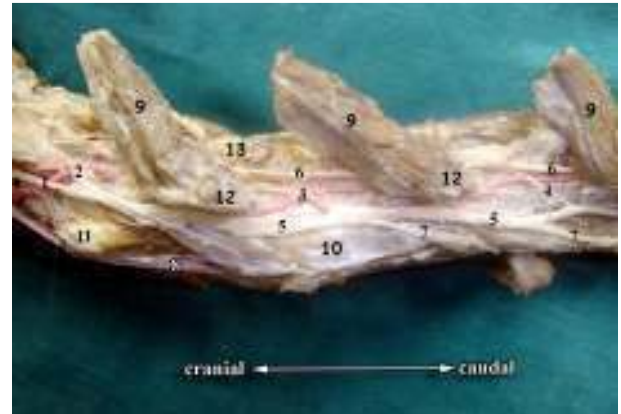
**Fig. (3):** A photograph of the tail of the buffalo (dorsolateral view), after removal of the dorsal muscles of the tail, showing origin and distribution of the first two caudal nerves: 1- N. sacralis V, 2- N. caudalis I, 3- N. caudalis II, 4- R. dorsalis N. Sacralis V 5- R. ventralis N. Sacralis V, 6- R. muscularis N. Sacralis V, 7- R. dorsalis N. Caudalis I 8- R. ventralis N. Caudalis I, 9- Plexus caudalis dorsalis, 10- A. caudalis dorsolateralis 11- Rr. caudales dorsales, 12- Mm. Intertransversarii caudae, 13- Processus transversus of the caudal vertebrae, 14- Processus articularis cranialis, 15- Processus spinosus, 16- M. Sacrocaudalis dorsalis lateralis.



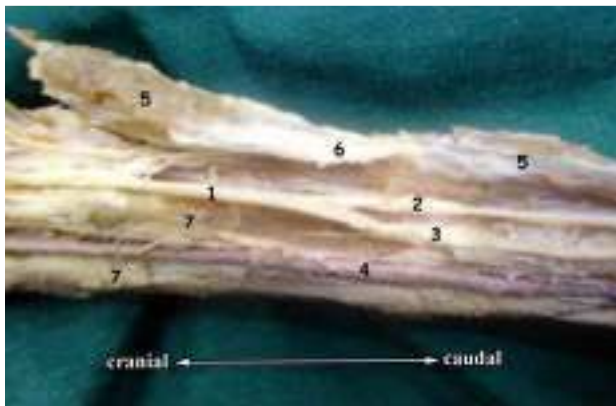
**Fig. (4):** A photograph of the tail of the buffalo (dorsolateral view), after removal of the dorsal muscles of the tail, showing origin and distribution of the first four caudal nerves: 1- N. sacralis V, 2- N. caudalis I, 3- N. caudalis II, 4- N. caudalis III, 5- N. caudalis IV 6- R. dorsalis N. sacralis V 7- R. ventralis N. sacralis V, 8- R. muscularis N. sacralis V., 9- R. dorsalis N. caudalis I, 10- R. ventralis N. caudalis I, 11- Plexus caudalis dorsalis, 12- Plexus caudalis ventralis, 13- A. caudalis dorsolateralis, 14- Processus articularis cranialis, 15- Processus spinosus 16- Mm. Intertransversarii caudae, 17- M. Sacrocaudalis dorsalis lateralis.



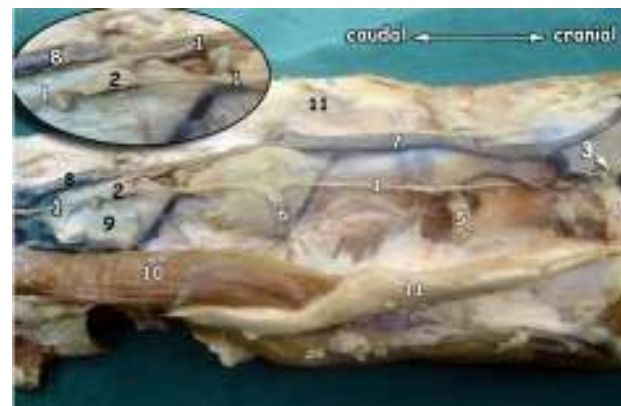
**Fig (5):** A photograph of the sacrocaudal region of the buffalo (ventral view), after removal of *M. sacrocaudalis ventralis medialis* showing the ventral branch of the first caudal nerve: 1- R. ventralis N. sacralis V, 2- R. ventralis N. caudalis I, 3- R. muscularis N. sacralis V 4- Plexus caudalis ventralis, 5- A. caudalis mediana, 6- Processus hemalis of the caudal vertebrae 7- *M. Sacrocaudalis ventralis lateralis*, 8- *M. Sacrocaudalis ventralis medialis*, 9- Ventral sacroiliac ligament.



**Fig (6):** A photograph of the tail of the buffalo (ventrolateral view), showing distribution of ventral branches of the first three caudal nerves: 1- R. ventralis N. sacralis V, 2- R. ventralis N. caudalis I, 3- R. ventralis N. caudalis II, 4- R. ventralis N. caudalis III, 5- Plexus caudalis ventralis, 6- Plexus caudalis dorsalis, 7- R. muscularis, 8- A. caudalis mediana, 9- *Mm. Intertransversarii caudae*, 10- *M. Sacrocaudalis ventralis medialis*, 11- Processus hemalis, 12- Processus transverses, 13- Processus articularis cranialis.



**Fig. (7):** A photograph of the tail of the buffalo (ventrolateral view), showing the ventral caudal nerve plexus at the level of the seventh caudal vertebra: 1- Plexus caudalis ventralis, 2- R. lateralis of Plexus caudalis ventralis, 3- R. medialis of Plexus caudalis ventralis, 4- A. caudalis mediana, 5- *Mm. Intertransversarii caudae*, 6- Processus transversus of the seventh caudal vertebra, 7- *Mm. Sacrocaudales ventrales mediales*.



**Fig. (8):** A photograph of the sacrocaudal region of the buffalo (ventrolateral view), after removal of *M. sacrocaudalis ventralis medialis*: 1- Truncus sympathicus, 2- Ganglion impar, 3- Ganglion sacralis, 4- Rr. ventrales N. sacralis III, 5- Rr. ventrales N. sacralis IV, 6- Rr. ventrales N. sacralis V, 7- V. sacralis mediana, 8- V. caudalis mediana, 9- Body of the vertebra caudalis I, 10- *M. Sacrocaudalis ventralis lateralis*, 11- Ventral sacroiliac ligament.

lateralis. During its course, this plexus detached cutaneous and muscular branches. The former supplied the skin, fascia and fat of the tail while, the muscular branches supplied the dorsal muscles of the tail and *Mm. intertransversarii caudae*. The dorsal caudal nerve plexus terminated at the distal end of the tail.

**Plexus caudalis ventralis.** The ventral caudal plexus appeared larger than the dorsal one (Fig., 2, 4 - 7). It was placed ventral to the transverse processes of the caudal vertebrae and *Mm. intertransversarii caudae* and dorsal to *Mm. sacrocaudales ventrales laterales*. During its course, it gave off cutaneous and muscular branches. The former supplied the skin, fascia and fat of the tail, while the muscular branches supplied the ventral coccygeal muscles. The plexus terminated as observed in the dorsal one.

At the level of the seventh caudal vertebra (Fig., 7/6), the ventral caudal nerve plexus was divided into two branches medial and lateral (Fig., 7/2,3). The former passed caudally within the vascular groove of the caudal vertebrae in accompany with the median caudal artery, while the lateral branch coursed caudally on the ventrolateral aspect of the *Mm. intertransversarii caudae* and each of them terminated at the distal end of the tail.

**A. Truncus sympathicus.** The sacral part of the sympathetic trunk passed on the ventrolateral aspect of the sacral segments (Fig., 8/1). At the pelvic sacral foramina, each sympathetic trunk presented a small spindle shape sacral ganglion, which detached a slender communicating branch to the corresponding ventral branch of the sacral spinal nerve. However, at the level of the sacrocaudal articulation the sacral part of the sympathetic trunk detached a communicating branch to the ventral caudal nerve plexus.

**B. Ganglion impar.** At the level of the first caudal vertebra, the sympathetic trunk of both sides united to enter a spindle shape impar ganglion (Fig., 8/3), from which a single caudal part of the sympathetic trunk originated and passed caudally within the vascular groove dorsal to the median caudal vessels (Fig., 8/1).

**C. Ganglia caudalia.** Behind the impar ganglion, the caudal part of the sympathetic trunk presented small, spindle-shape ganglia, between the first five caudal vertebrae. These ganglia provided the ventral caudal nerve plexus with communicating branches. These ganglia in addition to the caudal part of the sympathetic trunk could be traced behind the level of the fifth caudal vertebra.

**Rami communicantes.** The ventral branches of the third, fourth and fifth sacral spinal nerves provided fine communicating branches, which proceeded caudally to merge with the sacral part of the sympathetic trunk.

### Discussion

The present study in the buffalo revealed that the somatic innervation of the tail was represented by five pairs of caudal nerves. This finding was the same as observed in bovine (Budras *et al.*, 2003); ox (Rhagavan and Kachroo, 1964); sheep (May, 1970) and horse (Bradley, 1946; Rhagavan and Kachroo, 1964; Sisson and Grossman, 1968 and Budras *et al.*, 1994). However, different numbers of these caudal nerves were observed in other domestic animals as five to six pairs in bovine (Ghoshal, 1975), four to seven pairs (Ghoshal, 1975, in goat and dog and Evans and Christensen, 1979 and Wansbrough, 1996, in dog), fifteen pairs in camel (Smuts and Bezuidenhout, 1987) and four to eight pairs in pig (Ghoshal, 1975).

In this study, the dorsal branch of the first caudal nerve anaestmosed with the corresponding one of the last sacral nerve as observed by Bradley (1964), Sisson and Grossman (1968) in horse; Ghoshal (1975) in horse and pig and Evans and Christensen (1979) in dog. Moreover, the dorsal branch of the last sacral spinal nerve issues a muscular branch to innervate the adjoining dorsal muscles of the tail as detected by May (1970) in sheep and Bradley (1964) in horse. In the present study as well as Ghoshal (1975) in ruminants, pig and dog observed that the ventral branch of the last sacral nerve joined the ventral caudal plexus.

The current study revealed that the dorsal caudal nerve plexus passed caudally between the cranial articular and transverse processes of the caudal vertebrae in accompany with the dorsolateral caudal artery the *M. sacrocaudalis dorsalis lateralis* under cover. This was the same as observed by Sisson and Grossman (1968) and Ghoshal (1975) in horse, pig and dog and Evans and Christensen (1979) and Wansbrough (1996) in dog.

During the course of the dorsal caudal nerve plexus, it detached cutaneous and muscular branches, the former supplied the skin, fascia and fat of the tail, however, the muscular ones innervated the dorsal muscles of the tail and *Mm. intertransversarii caudae*. This nerve plexus terminated at the distal end of the tail, a result, which was in a line with the findings of Budras *et al.*, (2003) in bovines and Evans and Christensen (1979) in dog.

The current investigation and Ghoshal (1975) in pig and Evans and Christensen (1979) in dog observed that the ventral caudal nerve plexus appeared larger than the dorsal one. Moreover, the ventral caudal nerve plexus lay ventral to the transverse processes of the caudal vertebrae and *Mm. intertransversarii caudae*.

The same findings as Evans and Christensen (1979) in dog, this study detected that the ventral caudal nerve plexus gave off cutaneous and muscular branches in a manner like the dorsal one; the former supplied the skin, fascia and fat of the tail, while the muscular branches supplied the ventral coccygeal muscles and the plexus terminated at the distal end of the tail.

The current investigation revealed that the sacral part of the sympathetic trunk passed on the ventrolateral aspect of the sacral segments and presented a small, spindle shaped ganglion, which detached a communicating branch to the corresponding ventral branch of the sacral spinal nerve. Moreover, the sympathetic trunk detached a communicating branch to the ventral caudal nerve plexus at the level of the sacrocaudal articulation. These were the same as observed by Ghoshal (1975) in most of the domestic animals.

Ghoshal (1975) in ruminants and pig as well as the present study revealed that at the level of the first caudal vertebra, the sympathetic trunks of both sides united to enter a spindle shape impar ganglion, from which a single caudal part of the sympathetic trunk originated and ran caudally within the vascular groove dorsal to the median caudal vessels. However, Ghoshal (1975) observed that the impar ganglion in sheep was formed by the fusion of the last caudal ganglia. Bradley (1946), Sisson and Grossman (1968) and Ghoshal (1975) in horse asserted that the impar ganglion was formed by the union of the two medial branches of the sympathetic trunks.

The current investigation revealed that behind the impar ganglion, the caudal part of the sympathetic trunk presented small, spindle-shape ganglia, between the first five caudal vertebrae. These ganglia provided the ventral caudal nerve plexus with communicating branches. These ganglia in addition to the caudal part of the sympathetic trunk cannot be traced behind the level of the fifth caudal vertebra. However,

Ghoshal (1975) observed that the ganglia were very small in ox, sheep, pig and dog. They were found up to the sixth caudal segment in ox only

Ghoshal (1975) observed that the ganglia were very small in ox, sheep, pig and dog. They were found up to the sixth caudal segment in ox, only in the more cranial segments in sheep, in the first two or three caudal segments in goat, at the cranial three segments in pig and they were represented by five or six caudal ganglia in dog.

### References

- Bradley, O. C. (1946):** The Topographical anatomy of the thorax and abdomen of the horse. Revised by T. Grahame Second ed., W. Green and Son, Limited. Edinburgh.
- Budras, K. D., Sack, W. O. and Röck, S. (1994):** Anatomy of the horse (An illustrated text) Second ed., Schlütersche, Hanover and Mosby- Wolfe, London.
- Budras, K. D.; Habel, R. E.; Wünsche, A. and Buda, S. (2003):** Bovine anatomy (An illustrated text). First ed., Schlütersche GmbH & Co. KG., Verlag und Druckerei, Hanover, Germany.
- El-Ayat, M. A.; Hagra, S. M., Swielim, G. A. and Abuzaid, S. M. (1983):** Anatomical studies on the arterial blood supply of the tail in certain domestic animals (Buffalo, Camel and Donkey) Vet. Med. J., Vol. 31, No (3): 245-254.
- Evans, H. E. and Christensen, G. C. (1979):** In Miller's anatomy of the dog. Second ed., W.B. Saunders Company Philadelphia, London, Sydney and Tokyo.
- Gadre, K. M. (2000):** Coccygeal artery of buffalo calves. Indian Vet. J., 77 (1): 346
- Ghoshal, N. G. (1975):** Spinal nerves and autonomies in equine, ruminant, porcine and canine. In: Sisson and Grossman's "The anatomy of the domestic animals". Revised by Getty, R. (1975). Fifth ed., W.B. Saunders Company Philadelphia, London, Toronto.
- May, N. D. S. (1970):** The anatomy of sheep (A dissection manual) 3<sup>rd</sup> ed., University of Queensland Press. pp. 131, 132, 292 & 293.
- Nomina Anatomica Veterinaria (2005):** Fifth edition, prepared by the International Committee on Veterinary Gross Anatomical Nomenclature (I.C.V.G.A.N.) and authorized by the General Assembly of the World Association of Veterinary Anatomists (W.A.V.A.) Knoxville, TN (U.S.A.) 2003. Published by the Editorial Committee Hanover, Columbia, Gent, Sapporo.
- Raghavan, D. and Kachroo, P. (1964):** Anatomy of the ox (With comparative notes on the horse, dog and fowl) Indian Council of Agricultural Research, New Delhi.
- Sisson, S. and Grossman, J.D. (1968):** The anatomy of the domestic animals Fourth edition, W.B. Saunders Company, Philadelphia, London, Toronto.
- Smuts, M. M. S. and Bezuidenhout, A. J. (1987):** Anatomy of the dromedary, Clarendon Press, Oxford.
- Tawfik, M. G. (2007):** Some anatomical studies on the tail of the buffalo "Bos Bubalis L.". M.V.Sc., Thesis, Anat. and Embry., Fac. Vet. Med., Beni-Suef Univ., Beni-Suef, Egypt.
- Wansbrough, K. R. (1996):** Cosmetic tail docking of dog's tail. Aust. Vet. J., 74 (1):132-133.

### بعض الدراسات التشريحية على المدد العصبي للذئب في الجاموس

أشتملت مادة هذا البحث على ذبول عشرة من الجاموس البالغة السليمة ظاهرياً ، وقد تم تشريحها لتوضيح مددها العصبي. ووضحت نتائج الدراسة في ثمانية صور فوتوغرافية ، وأظهرت الدراسة أن المدد العصبي للذئب من خلال خمسة اعصاب ذيلية وقد تم دراسة منشأها ومسارها وتوزيعها في أجزاء الذئب ، كما تم دراسة المدد السمبثاوي والباراسمبثاوي للذئب.